

Implantology

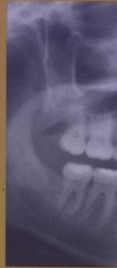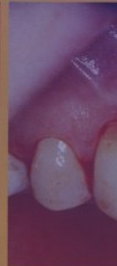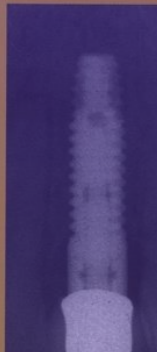


Table 1
Total patient distribution

Total	Total Central	Lateral	Canine	Patients	Sites
Male	0.93% 3	10.05% 33 (4 with bilateral)	0	36	40
Female	0.6% 2	84.15% 276 (16 with bilateral)	4.27% 14 (1 bilateral)	292	309
Total	1.53% 5	94.2% 309	4.27% 14	328	349

15 years of studies done with 328 patients (adolescent)

Treatment	Tooth	Patient			Site
Close		Male	Female	Total	
	Central	0	0	0	/
	Lateral	15	32	47	47
	Canine	0	4	4	4
	Total Close	15 ^a (4.6%) 15 ^b	36 ^a (11%) 36 ^b	51 (15.6%)	51
Open	Central	3	2	5	5
	Lateral	18 14+(4x2)=22 22 ^b	244 ^a 228+(16x2)= 260 ^b	262	282
	Canine	0	10 ^a 9+2=11 ^b	10	11
	Total Open	21 ^a (6.4%) 25 ^b	256 ^a (78%) 273 ^b	277 (84.4%)	298
	Total Patient	36 (11%)	292 (89%)	328 (100%)	349

^a Patient; ^b Site

Source: Misch, d'Alessio, "ORAL HEALTH" - Aug 2005

15 years of studies done with 328 patients (adolescent)

Table 3						
Treatment selection after space opening						
Patient		Implant Number		Patient	FPD Number	
Male	Central	1	1	Male	Central	2
	Lateral	14	18 (4 bilateral)		Lateral	4
	Canine	0	0		Cuspid	0
Female	Central	2	2	Female	Central	0
	Lateral	232	248 (16 bilateral)		Lateral	12
	Canine	6	7 (1 bilateral)		Cuspid	4
		255	276			22
		92%				8%
						22 FPD

Source: Misch, d'Alessio, "ORAL HEALTH" - Aug 2005

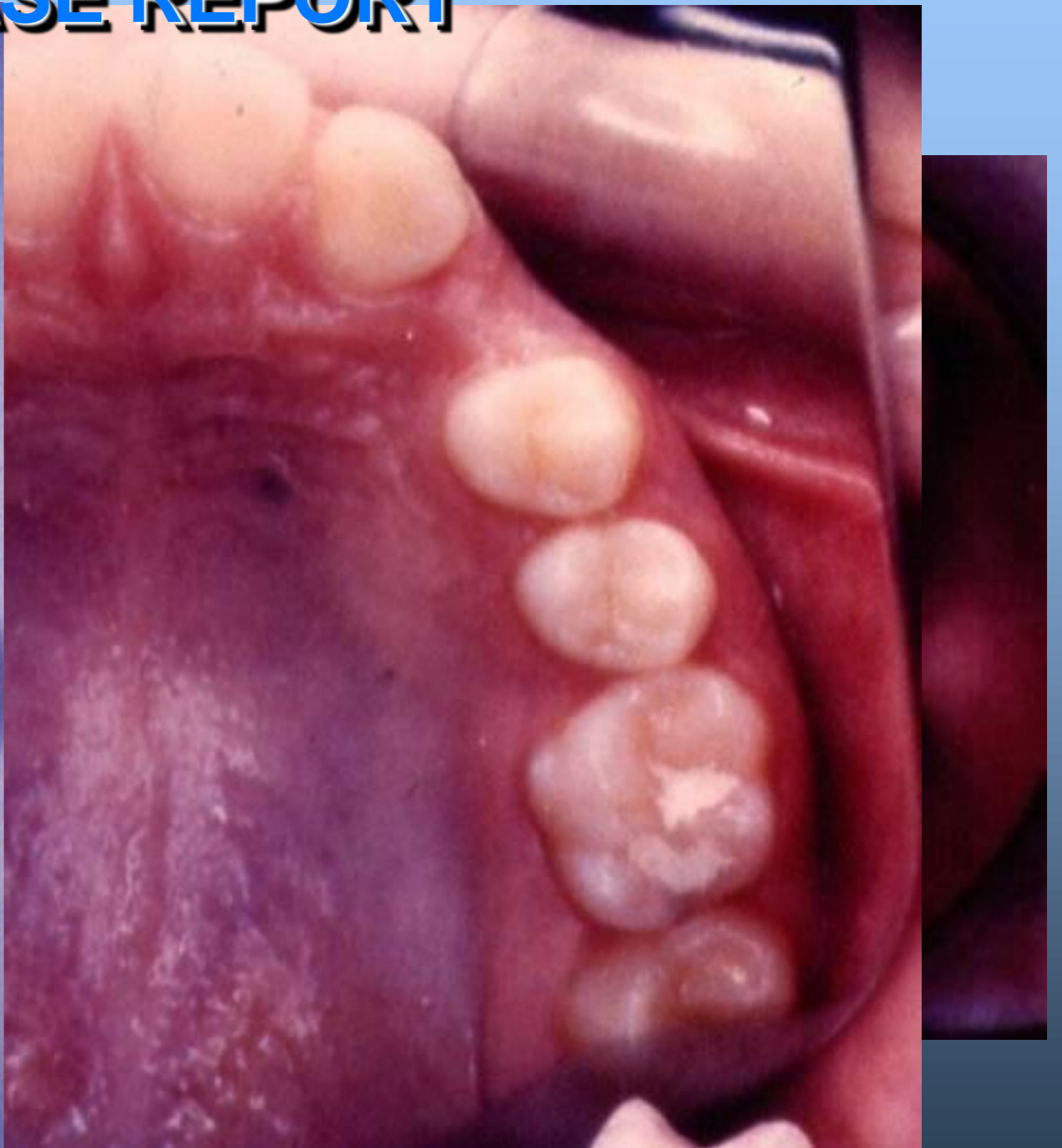
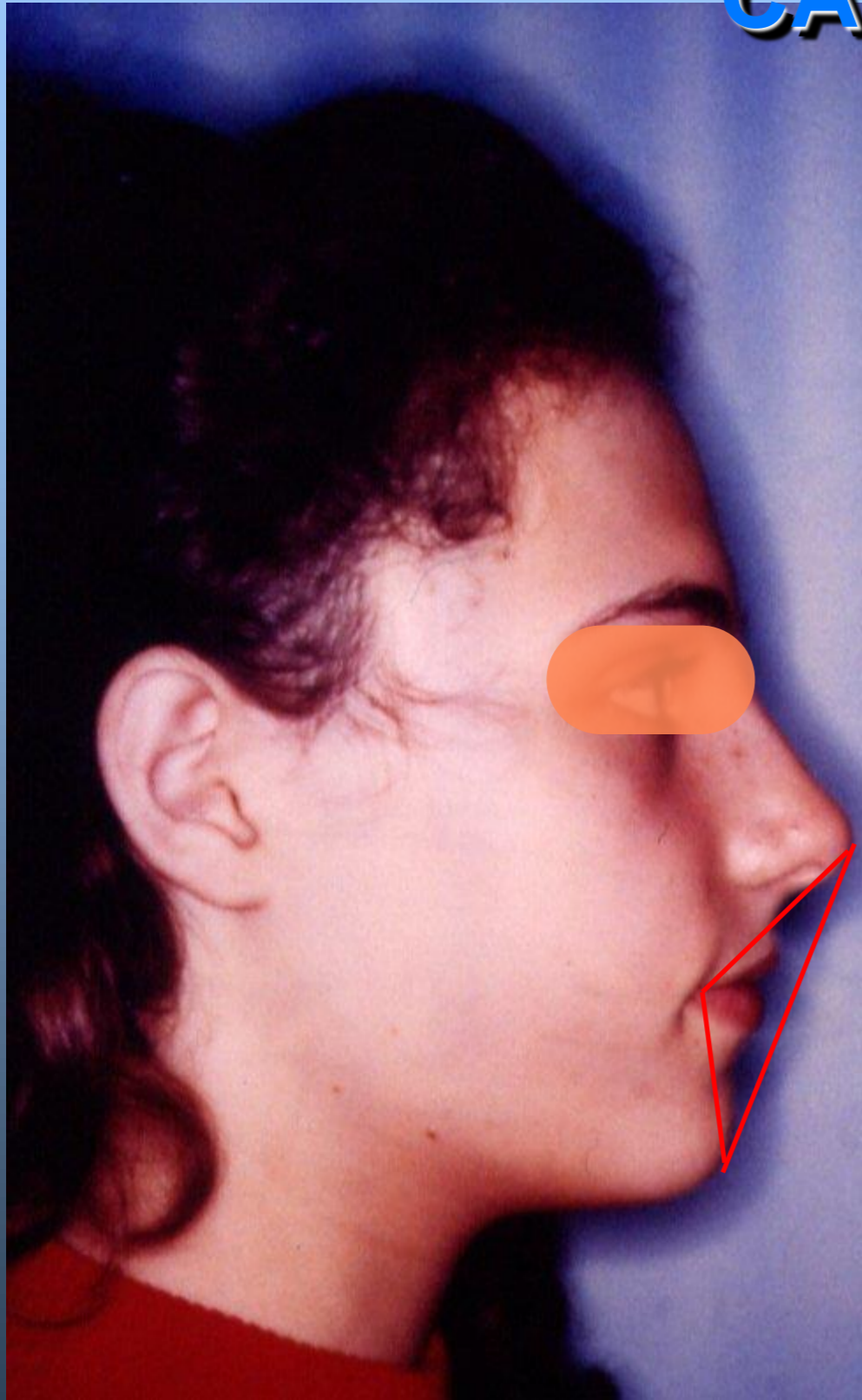
15 years of studies done with 328 patients (adolescent)

Table 4

Site	Implant (mm) Diameter	Length (mm)	Total Number	Failed/ Replaced
Central	3.5	12	1	—
	3.75	13	1	—
	4	12	1	—
Lateral	3.50	12	187	2
	3.75	13	25	2
	3.75	16	54	—
Canine	3.5	12	1	—
	3.75	13	2	—
	4	12	4	—

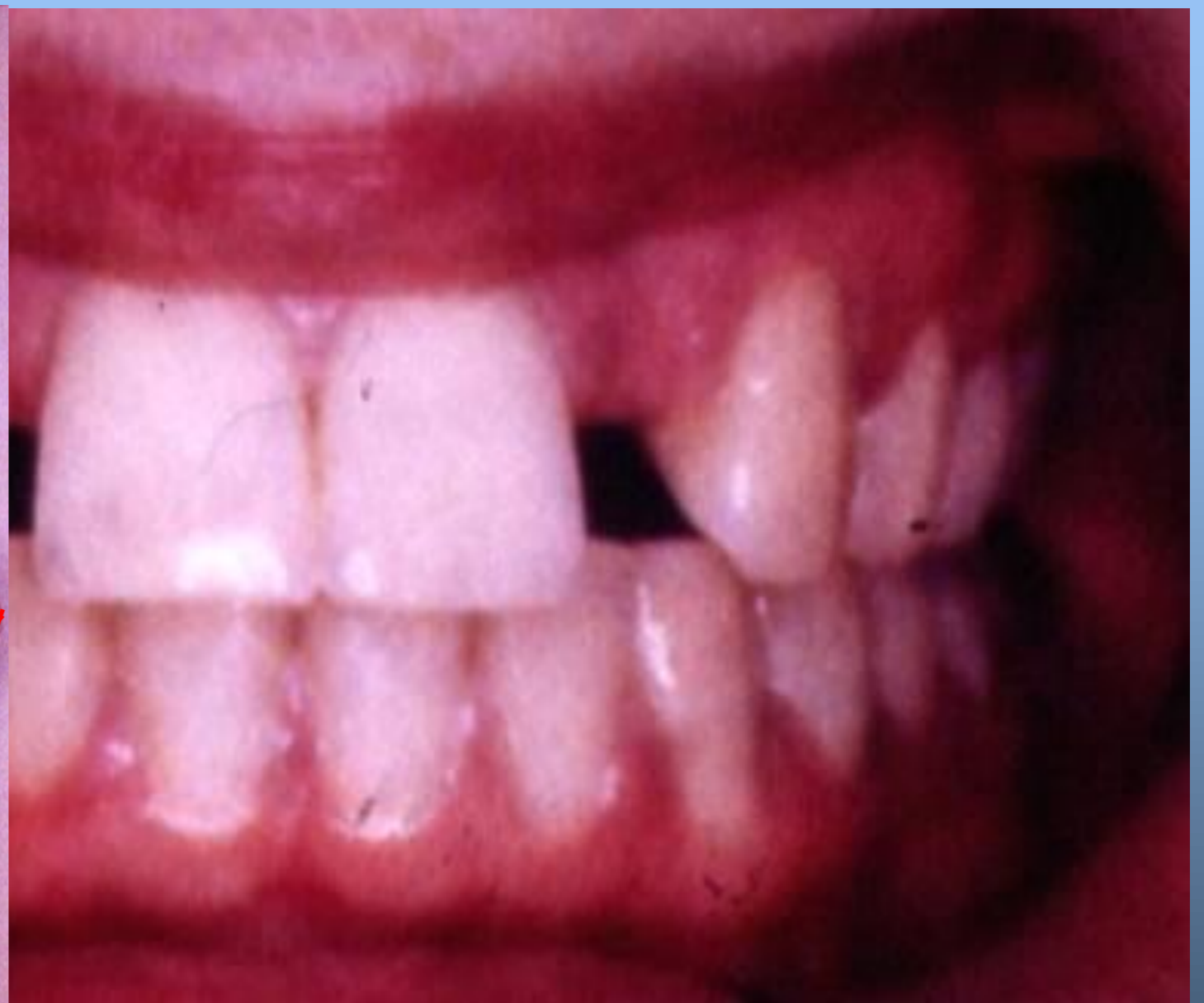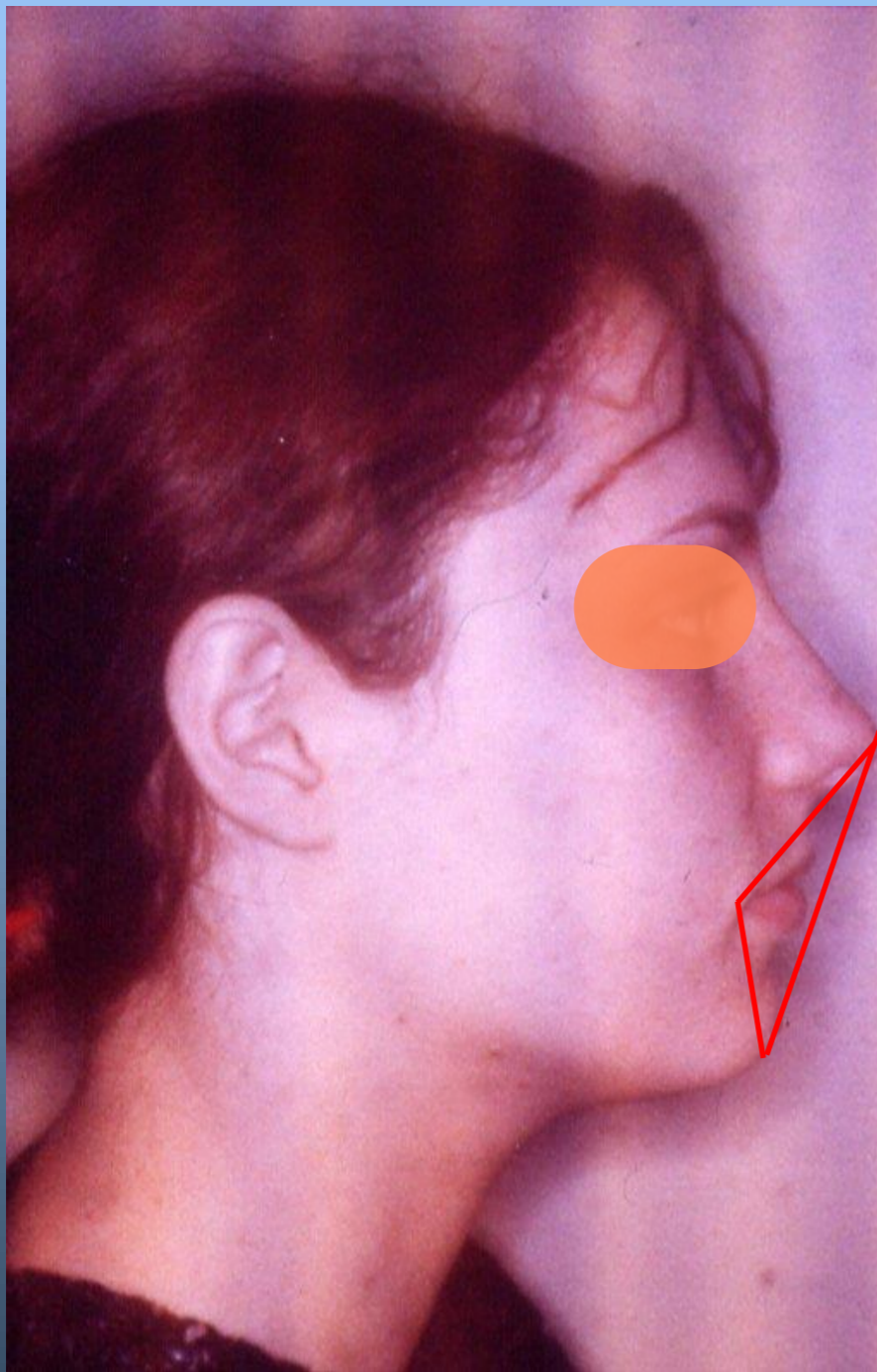
Source: Misch, d'Alessio, "ORAL HEALTH" - Aug 2005

CASE REPORT



Source: Agnesia 1.2 2.2 (1996)

CASE REPORT



“La protesi FP-1 e’ fissa e molto naturale ... e di ideale inserimento dei due impianti”
Carl E. Misch, Francine Dietsch-Misch – Contemporary implant dentistry 1999 p. 541

QuickTime™ e un
decompressore Codec YUV420
sono necessari per visualizzare quest'immagine.

QuickTime™ e un
decompressore Codec YUV420
sono necessari per visualizzare quest'immagine.

QuickTime™ e un
decompressore Codec YUV420
sono necessari per visualizzare quest'immagine.

QuickTime™ e un
decompressore Codec YUV420
sono necessari per visualizzare quest'immagine.

CONCLUSION

Implant in conjunction with space opening to replace congenitally missing teeth is the treatment of choice. Cooperation between the two disciplines is paramount to treatment success.

Miss Italia 2005

